

Wound Type

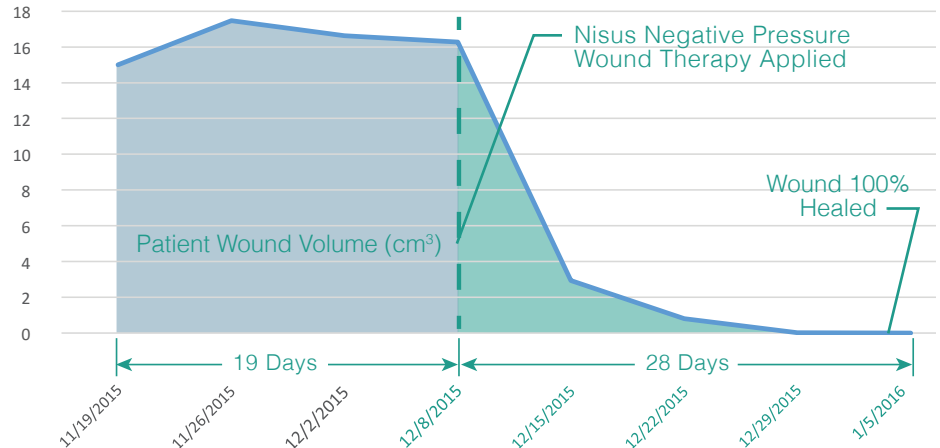
Stage IV Pressure Ulcer
Location: Left Ischium
Date Wound Acquired: 9/16/15
Patient Age: 53
Patient Weight:

History and Physical

53 year-old male presented to LTC with stage IV pressure ulcer to the left ischium. Patient admit date to LTC facility was 11/19/15.

Past Medical History

CHF, insulin dependent diabetic, immobility, extremity muscle contractures, and dysphagia.


Initial Findings

Patient present with a stage IV pressure ulcer to the left ischium. Wound was acquired on 09/19/15. Initial measurement of wound was length of 2.0 cm by width of 3.0 by depth of 2.5 cm. No prior measurements are obtainable from previous medical record. Wound had minimal serous drainage and 90% granulation tissue and 10% necrotic tissue.

Course of Treatment

Course of treatment starting on 11/19/15 was a primary dressing of a silver alginate covered with a gauze secondary dressing. On 11/26/15 wound showed no signs of improvement and modality of treatment was changed to a primary dressing of a silver hydrogel covered with a gauze secondary dressing. On 12/2/15 wound showed slight improvement in measurements, current treatment was continued at this time.

On 12/8/15 wound showed no signs of improvements from previous week; Nisus NPWT applied at this time. On 12/15/15 with mark improvement to wound and Nisus NPWT system continued. Patient seen on 12/22/15 with mark improvement in wound measurements and Nisus NPWT system continued. On 12/29/15 wound measurements were .1 cm by .2 cm by .3cm and Nisus NPWT system was discontinued and a messalt packing placed. On 1/5/16 the wound was healed.

Date	Modality of Treatment	Weeks in Treatment	Length (cm)	Width (cm)	Depth (cm)	Volume (cm)
11/19/2015	Silver alginate	9	2	3	2.5	15.00
11/26/2015	Silver hydrogel	10	2.1	3.2	2.6	17.47
12/2/2015	Silver hydrogel	11	2	3.2	2.6	16.64
12/8/2015	Nisus NPWT applied	12	2.1	3.1	2.5	16.28
12/15/2015	Nisus NPWT	13	1.5	1.4	1.4	2.94
12/22/2015	Nisus NPWT	14	1	0.8	1	0.80
12/29/2015	Nisus NPWT discontinued / Messalt applied	15	0.1	0.2	0.3	0.01
1/5/2016	Wound completely healed	16	0	0	0	0.00