

Wound Type

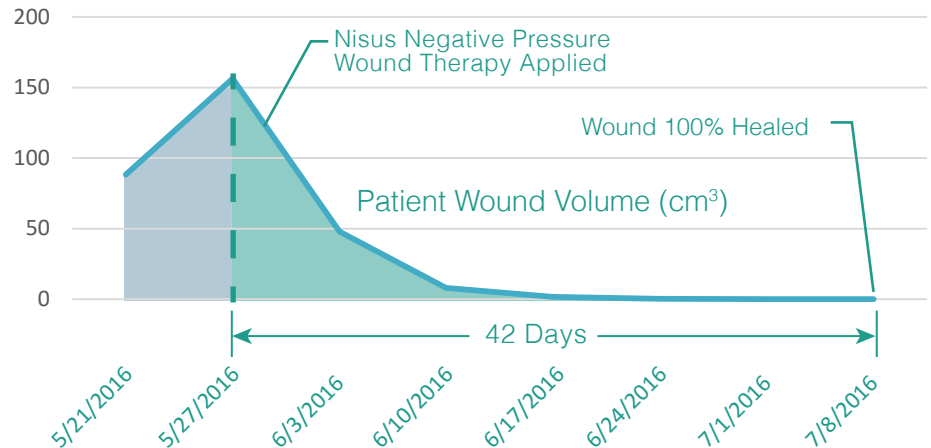
Venous Stasis
 Location: Right lower leg
 Date Wound Acquired: 05/17/16
 Patient Age: 57

History and Physical

A 57 year old male presented with venous stasis ulcer to right lower leg.

Past Medical History

Patient has past medical history of CHF, insulin dependent diabetes, COPD, HTN, and obesity. Patient has significant history of venous stasis ulcers.


Initial Findings

Patient presented to facility on 5/21/16 with a full thickness injury to his right lower leg, etiology of venous stasis ulcer. Initial measurements were length of 21 cm, width of 14 cm, and depth of 0.3 cm. Treatment at the time of admission was silver alginate with a secondary dressing of kerlix and light compression.

Course of Treatment

Patient was being treated at an acute care facility with calcium alginate and light compression therapy. Upon admission to the extended care facility, the same course of treatment was continued. On 5/27/16, wound measurements were length of 23 cm, width of 17 cm, and depth of 0.4 cm. At this time, the Nisus NPWT platform was placed with light compression. Over the next 4 weeks, the wound continued to make noticeable improvement with the Nisus NPWT platform and light compression.

On 6/24/16, the Nisus NPWT platform was discontinued and a contact layer was placed with light compression. The wound had complete closure on 7/8/16.

Date	Modality of Treatment	Weeks in Treatment	Length (cm)	Width (cm)	Depth (cm)	Volume (cm)
5/21/2016	Calcium alginate and light compression	1	21	14	0.3	88.2
5/27/2016	Nisus NPWT and light compression	2	23	17	0.4	156.4
6/3/2016	Nisus NPWT and light compression	3	16	10	0.3	48
6/10/2016	Nisus NPWT and light compression	4	8	5	0.2	8
6/17/2016	Nisus NPWT and light compression	5	4	2	0.2	1.6
6/24/2016	Nisus NPWT discontinued and contact layer with light compression applied	6	2	1	0.1	0.2
7/1/2016	Contact layer and light compression	7	0.5	0.2	0.1	0.01
7/8/2016	Wound completely healed	8	0	0	0	0