

Wound Type

Non-healing Surgical Wound / Pilonidal Cyst
 Location: Gluteal Fold
 Date Wound Acquired: 02/16/16
 Patient Age: 26

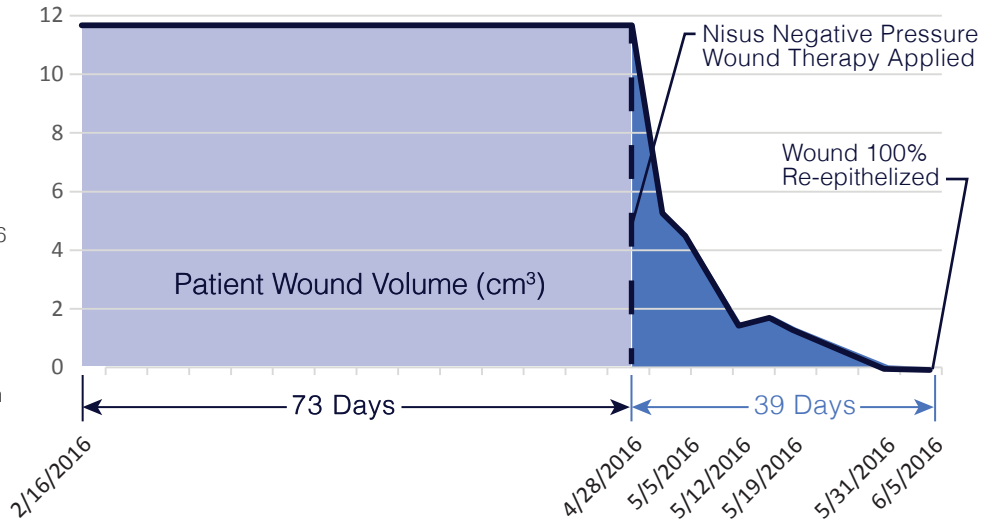
History and Physical

26 year-old male presented with pilonidal cyst. Pilonidal cystectomy was performed on 2/16/16 and wound was being treated with a variety of dressings, including another NPWT platform.

Patient underwent a surgical debridement on 4/27/16 and the Nisus NPWT platform was applied post operatively. Patient was then seen at the wound center on 4/28/16 for treatment.

Past Medical History

The patient has a history of depression.



Initial Findings

Patient presented with a non-healing surgical wound on 4/28/16. Wound was acquired on 02/16/16 secondary to a pilonidal cystectomy. Surgical debridement occurred on 4/27/16, prior treatment was moist saline dressing. Patient was referred to wound center on 4/27/16. Initial measurement of wound on 4/28/16 was length of 3.43 cm by width of 1.36 by depth of 2.5 cm. No prior measurements are obtainable from the previous medical record. Wound had moderate sanguineous drainage.

Course of Treatment

A pilonidal cystectomy was performed on 2/16/16. Patient had several modalities of treatments from 2/26/16 to 4/28/16. Patient was seen at the wound center on 4/28/16 one day post surgical for debridement of the wound. The Nisus NPWT platform was initiated on 4/27/16. The Nisus NPWT platform was utilized until 5/31/16. The Nisus was discontinued at this time secondary to the wound being superficial. The wound had complete closure on 6/6/16.

Date	Modality of Treatment	Weeks in Treatment	Length (cm)	Width (cm)	Depth (cm)	Volume (cm)
2/16/16	Wound acquired	0	3.43	1.36	2.5	11.66
4/28/2016	Nisus NPWT platform	9	3.43	1.36	2.5	11.66
5/2/2016	Nisus NPWT platform	10	2.58	1.37	1.5	5.30
5/5/2016	Nisus NPWT platform	11	2.14	1.41	1.5	4.53
5/12/2016	Nisus NPWT platform	12	2.48	1.2	0.5	1.49
5/16/2016	Nisus NPWT platform	12	2.94	1.2	0.5	1.76
5/19/2016	Nisus NPWT platform	13	2.04	0.95	0.7	1.36
5/31/2016	Nisus NPWT discontinued	14	0.5	0.29	0.2	0.03
6/6/2016	Wound completely healed	15	0	0	0	0.00