

Wound Type

Non-healing surgical
 Location: Abdomen wall
 Date Wound Acquired: 4/21/16
 Patient Age: 58

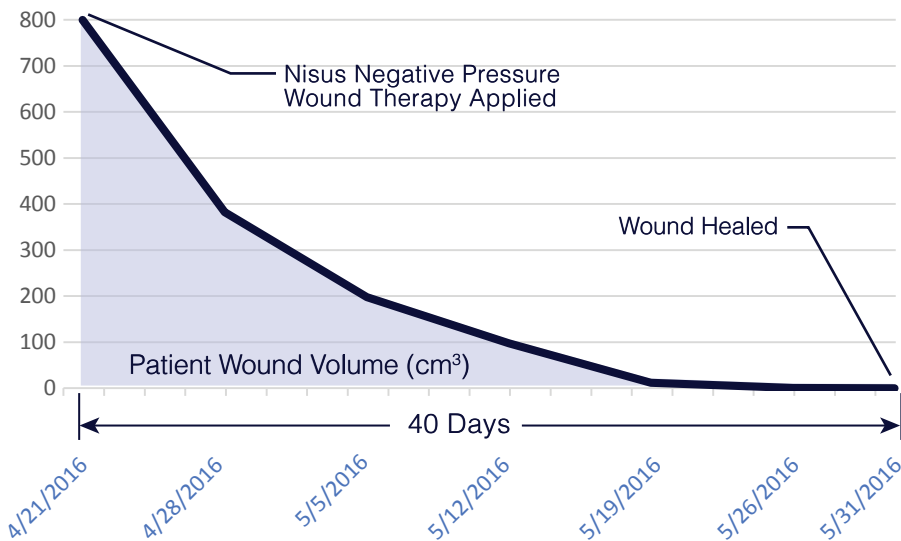
History and Physical

58 year old male presented to the ED with abdominal pain. CT scan showed a perforation of the small bowel, emergency surgery performed.

The fascia was closed during the procedure and the Nisus NPWT platform applied immediately post-operative.

Past Medical History

Patient has history of DM, obesity, CHF, COPD, and 25 pack per year cigarette smoker.



Initial Findings

Post-operative wound measurements were length of 16 cm, width of 10 cm, and depth of 5 cm. The wound pre-operatively is 100% pink and with minimal serous drainage. The Nisus NPWT platform was applied at this time.

Course of Treatment

The Nisus NPWT was applied immediately post operatively to the mid abdominal surgery on 4/21/16. The primary modality of treatment for this wound was the Nisus NPWT platform. The patient required one excisional debridement on 5/5/16, secondary to 10% of the wound bed contained firmly adherent slough.

The Nisus NPWT was discontinued on 5/31/16 and the wound was completely closed on 6/7/16.

Date	Modality of Treatment	Weeks in Treatment	Length (cm)	Width (cm)	Depth (cm)	Volume (cm)
4/21/2016	Nisus NPWT platform initiated	0	16	10	5	800.00
4/28/2016	Nisus NPWT platform	1	13	7	4.2	382.20
5/5/2016	Nisus NPWT platform and debridement	2	11	5	3.6	198.00
5/12/2016	Nisus NPWT platform	3	8.1	4.3	2.8	97.52
5/19/2016	Nisus NPWT platform	4	4.2	2.4	1.2	12.10
5/26/2016	Nisus NPWT platform	5	1.8	1.1	0.3	0.59
5/31/2016	NPWT discontinued and contact layer applied	6	0.6	0.2	0.1	0.01
6/07/2016	Wound completely healed	7	0	0	0	0.00