

Wound Type

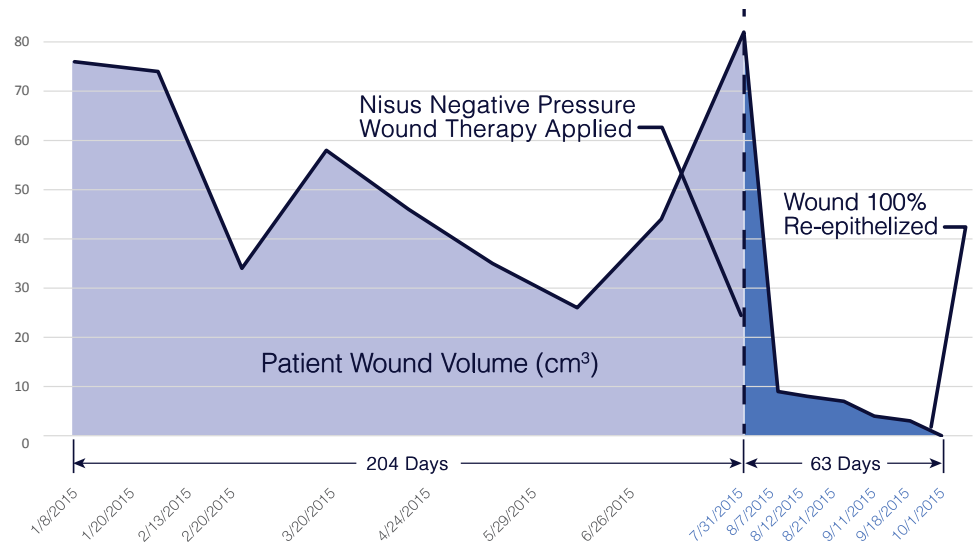
Diabetic / Ulcer of the Left Lower Extremity
 Location: Calcaneous
 Date Wound Acquired: 01/08/2015
 Patient Age: 68
 Patient Weight: 118 Kg

History and Physical

68 year-old Caucasian male presented to the wound clinic on 01/08/2015 with primary complaint of wound to the left heel.

Past Medical History

Insulin dependent diabetes, PVD, PAD, CHF, CAD, and 40 pack year cigarette smoker.
 Patient states the wound has been present for a month prior to being seen at the clinic. Patient states he has been treating with gauze dressing for the last month.



Initial Findings

Patient has Grade 3 Ulcer to left calcaneous. The wound has measurements length of 6.5 cm, width of 11.6 cm, depth of 1.3 cm, and cubic volume of 77 cm³. Wound bed presented with 90% unstable necrotic tissue, 10% pink tissue, and small amount of serous drainage.

Course of Treatment

Initial excisional debridement occurred on 01/20/15 and modality of treatment was a silver alginate. On 01/30/15 no improvement of wound and modality of treatment changed to a skin substitute. On 02/13/15 wound bed appeared with 90% necrotic tissue and excisional debridement performed and continued modality of treatment of skin substitute. On 02/20/2015, upon exam patient had absence of pedal and posterior tibial pulses, via Doppler. Patient underwent an emergent re-vascularization of the left leg. Post procedure a skin substitute was placed. Between 02/20/15 to 07/31/15 patient underwent multiple excisional debridement's and several modalities of treatment with no wound improvement. Amputation of left lower extremity was considered.

On 07/31/15 the Nisus NPWT wound system was applied. On 08/07/15 wound showed marked improvement and appeared with 10% percent necrotic tissue and excisional debridement performed. Between 07/31/15 to 09/18/15 patient modality of treatment was Nisus NPWT wound system, patient had 2 more excisional debridement's for small clean up of necrotic tissue. On 09/18/15 The Nisus NPWT wound system was DC secondary to wound is 100 granulated and is ready for re-epithelization. On 10/01/15 the wound was 100% re-epithelized.

Date	Modality of Treatment	Weeks in Treatment	Length (cm)	Width (cm)	Depth (cm)	Volume (cm)
1/8/15	AG Alginate	0	6.5	11.6	1.3	76
1/20/15	Debridement / Skin Substitute	1	6.3	12.4	1.2	74
2/13/15	Debridement / Skin Substitute	5	5.5	11	0.7	34
2/20/15	Procedure	6	10.7	11	1.1	58
3/20/15	Hydrogel and secondary dressing	10	6.5	10	1	46
4/24/15	Debridement / Skin Substitute	15	5.2	10.8	0.9	35
5/29/15	Skin substitute	20	6.4	10.4	0.6	26
6/26/15	Hydrogel and secondary dressing	24	7.3	11	0.7	44
7/31/15	Nisus NPWT Applied	29	5.5	11	1.5	82
8/7/15	Nisus NPWT/debridement	30	6	10	0.2	9
8/12/15	Nisus NPWT/debridement	30	5.3	9.8	0.2	8
8/21/15	Nisus NPWT	32	4.8	10	0.2	7
9/11/15	Nisus NPWT/debridement	35	4.5	10	0.1	4
9/18/15	Nisus NPWT D/C and hydrogel	36	5.5	7	0.1	3
10/1/15	Wound completely healed	38	0	0	0	0